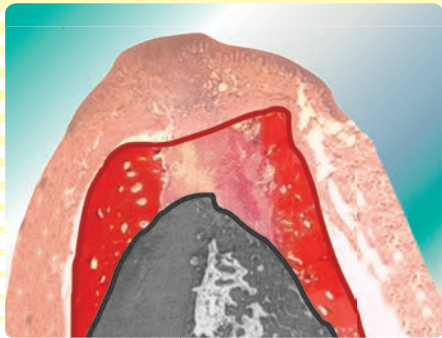


# Regeneration



The complete solution for the alveolar ridge

## The Regeneration therapy concept

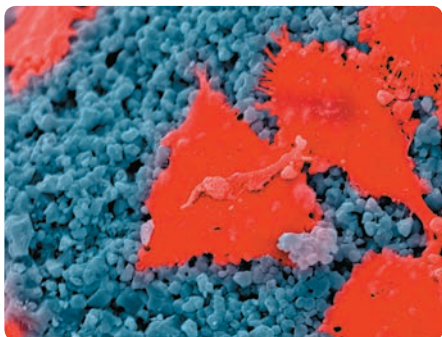


alveoprotect

The kind of advanced bone loss associated with late-stage implantation or jaws already suffering from (possibly significant) atrophy often requires extensive and costly augmentations.

This surgical intervention calls for an experienced surgeon. bredent medical can help retain and develop the jaw bone in such cases with its safe and user-friendly solutions, which complement each other perfectly to form an overall therapy concept.

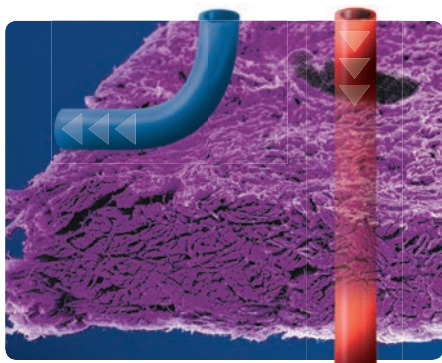
The component parts of the Regeneration therapy concept - alveoprotect collagen fleece, ossceram nano bone-grafting material, and the angiopore selectively permeable membrane - are all the materials you need to prevent bone loss as early as the extraction stage, help form new bone, and promote conversion of the bone replacement material applied.



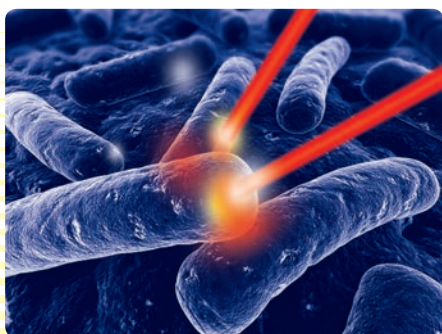
ossceram nano

You can further reinforce the benefits of surgical intervention by incorporating HELBO therapy as well. The antimicrobial photodynamic therapy used in the HELBO process provides effective control of bacteria, restores the natural balance, and significantly reduces complications as a result. Various studies and specialist articles have provided scientific evidence of this.


You can therefore ensure the implants inserted afterwards benefit from ideal healing conditions and long-term stability.




angiopore



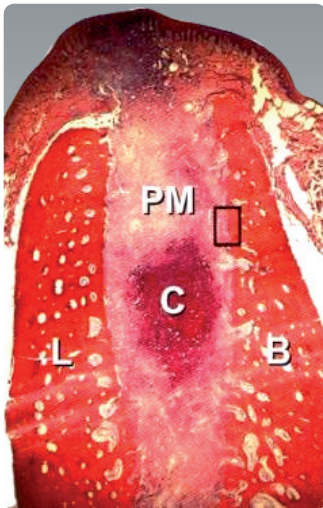
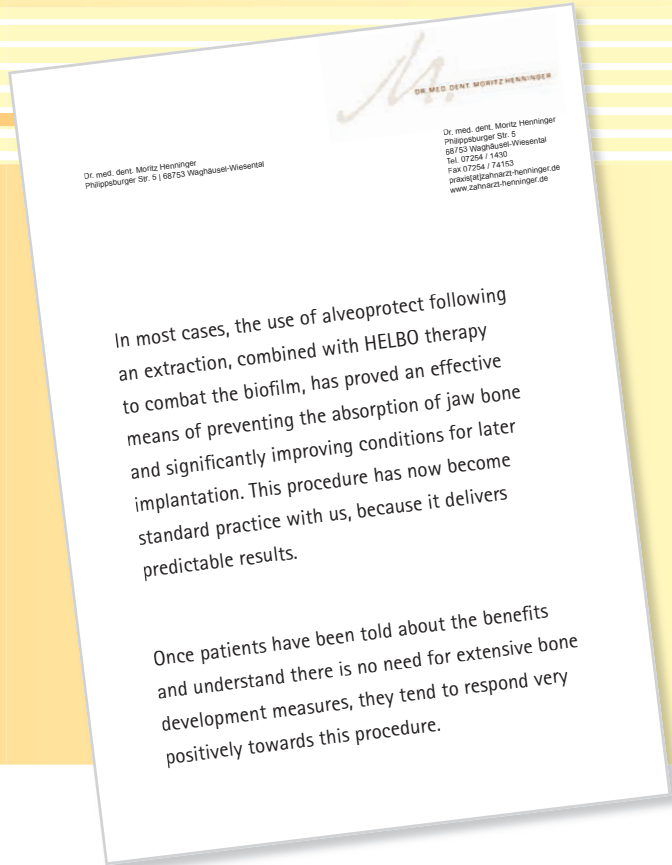HELBO®



alveoprotect



Dr. Moritz Henninger, Wiesenthal (Germany)

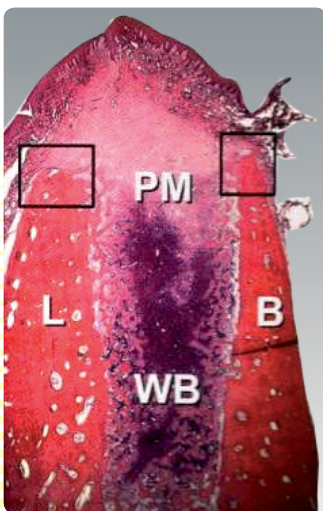


Bone absorption following dental extraction after 1 week


The conservative approach to extraction, whereby **the alveolus and buccal bone lamella are retained**, creates more favourable conditions for implant therapy compared with wholesale osteotomy. In fact, this kind of wholesale osteotomy used for extraction purposes or to deal with defects is often associated with extensive and costly augmentation work.

alveoprotect is a **highly biocompatible and quickly absorbable collagen** made from **porcine dermis (type I and III collagen)**, which enables you to **stabilise the alveolus and support the buccal lamella**. You can safeguard the intervention and the subsequent implant therapy by significantly reducing complication rates if you also use antimicrobial photodynamic therapy based on the HELBO process. The patient is spared the prospect of extensive and costly augmentation work.

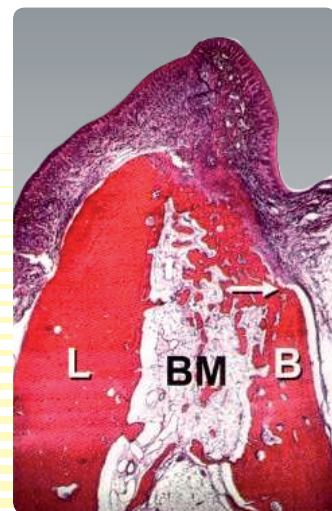
Dimensional ridge alterations following tooth extraction. An experimental study in the dog. Araujo et al., J Clin Periodontol. 32: 212-218 (2005)



After 2 weeks



After 4 weeks



After 8 weeks

# Collagen fleece for socket preservation

## Properties

Hemostatic agent with short-term barrier function, i. e.

- *alveoprotect* encourages clot formation of the blood
- stabilizes the blood coagulum
- counteracts wound contraction
- protects the wound for approx. 2 – 4 weeks
- is superficially epithelialised
- encourages new bone formation
- is entirely reabsorbed

## Processing

*alveoprotect* is easily processed

- Depending on the indication, the thickness of *alveoprotect* is adjustable by moisturizing and compression
- *alveoprotect* is easily cut to the desired size
- *alveoprotect* absorbs wound blood like a sponge
- *alveoprotect* is structurally stable, pliable and adapts to its surroundings
- *alveoprotect* remains location and volume stable after application
- A plastic covering of the alveole is not required

## Benefits

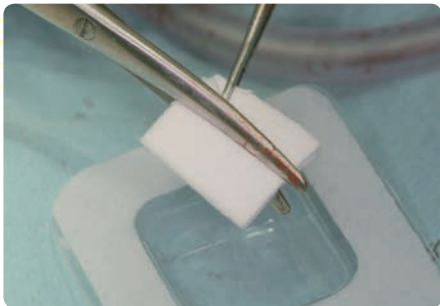
- *alveoprotect* is an ideal frame for the adsorption of thrombocytes, fibroblasts and osteoblasts.
- It encourages coagulum formation, as contact with blood leads to an aggregation of thrombocytes.
- Due to its high hydrophilic properties and interconnective porosities, *alveoprotect* absorbs blood quickly
- The vestibular bone lamella of the extraction alveole is supported
- *alveoprotect* is ph-neutral and exerts a positive effect on soft tissue reactions

## Indications

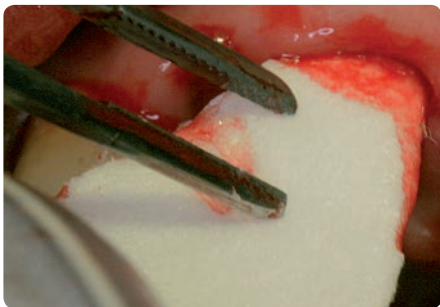
- Socket preservation
- Haemostyptic extraction wound therapy for patients presenting a haemorrhage risk (Marcumar, aspirin)
- Sinus floor elevation
  - Protection or repair of the Schneiderian membrane
  - Covering of the lateral window
- Peri-implantar bone defects associated with immediate implantation
- Filling the gap caused by the expansion associated with bone splitting
- Filling of jaw defects (e.g. following a cystectomy)




*alveoprotect* fleece (20 x 20 x 4 mm)



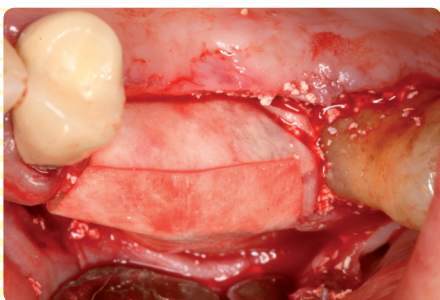
Cutting to size



Soaks up wound blood like a sponge



SEM image of *alveoprotect* (enlarged 300 x)



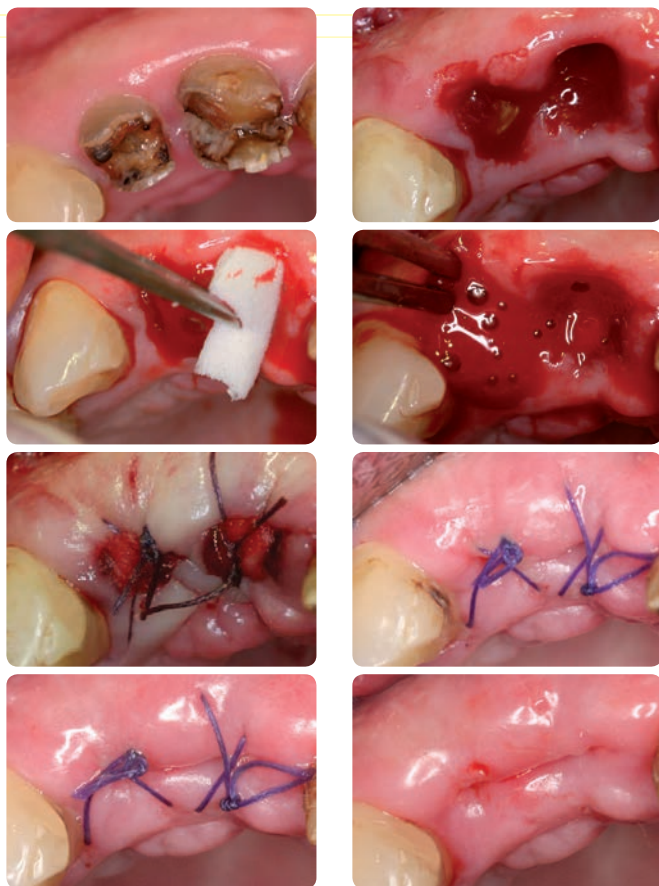
Covering of augmentation work

## Socket Preservation

Various scientific studies have revealed that

- significant bone reduction usually occurs within a few weeks after a tooth extraction, whereby the vestibular bone lamellae is particularly affected
- this bone reduction is reducible through the user of various materials for socket preservation
- the healing process normally is considerably extended at the same time, because the entire remodelling of replacement material may take a lot of time
- a significantly higher complication rate is observable during the use of bone substitute materials.

## Clinical case



PD Dr. Dr. Rothamel, University of Cologne

Extraction of two maxillary teeth. Particular attention is paid to the prevention of vestibular bone lamella damage. Utilisation of Periostomes, if necessary. Careful extraction without subsequent digital compression.

Remove *alveoprotect* from the sterile package and cut to size with scissors, if necessary. The cut sections are placed into the alveole in dry condition. The alveole is completely filled with condensing *alveoprotect* too much.

*alveoprotect* is immediately saturated with blood, de-aerates itself and stabilises at the alveolar walls.

Following that, an adapting suture is inserted. A total closure of the wound is not required.

After four days postoperative, neither swelling nor inflammation reactions are visible. *alveoprotect* accelerated the healing process. Epithelisation occurs via the organized *alveoprotect*.

The sutures were removed after six days.

## Further reading

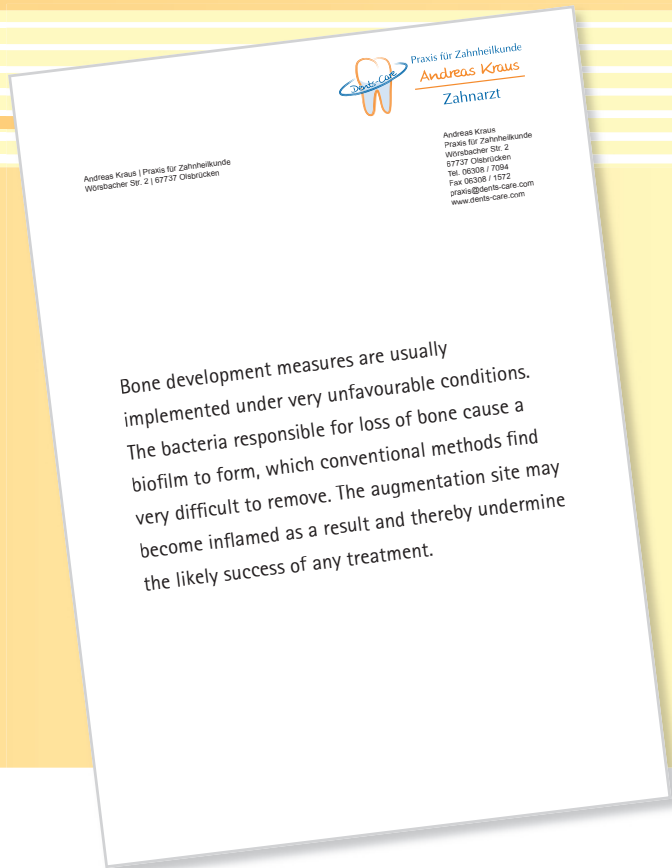
- Araujo, M. G. and J. Lindhe (2005). Dimensional ridge alterations following tooth extraction. An experimental study in the dog. *J Clin Periodontol* 32(2): 212-8.
- Araujo, M. G., F. Sukekava, J. L. Wennstrom and J. Lindhe (2005). Ridge alterations following implant placement in fresh extraction sockets: an experimental study in the dog. *J Clin Periodontol* 32(6): 645-52.
- lasella, J. M., H. Greenwell, R. L. Miller, M. Hill, C. Drisko, A. A. Bohra and J. P. Scheetz (2003). Ridge preservation with freeze-dried bone allograft and a collagen membrane compared to extraction alone for implant site development: a clinical and histologic study in humans. *J Periodontol* 74(7): 990-9.
- Lekovic, V., P. M. Camargo, P. R. Klokkevold, M. Weinlaender, E. B. Kenney, B. Dimitrijevic and M. Nedic (1998). Preservation of alveolar bone in extraction sockets using bioabsorbable membranes. *J Periodontol* 69(9): 1044-9.
- Lekovic, V., E. B. Kenney, M. Weinlaender, T. Han, P. Klokkevold, M. Nedic and M. Orsini (1997). A bone regenerative approach to alveolar ridge maintenance following tooth extraction. Report of 10 cases. *J Periodontol* 68(6): 563-70.
- Schropp, L., A. Wenzel, L. Kostopoulos and T. Karring (2003). Bone healing and soft tissue contour changes following single-tooth extraction: a clinical and radiographic 12-month prospective study. *Int J Periodontics Restorative Dent* 23(4): 313-23.
- Simon, B. I., S. Von Hagen, M. J. Deasy, M. Faldu and D. Resnansky (2000). Changes in alveolar bone height and width following ridge augmentation using bone graft and membranes. *J Periodontol* 71(11): 1774-91.
- Yilmaz, S., E. Efeoglu and A. R. Kilic (1998). Alveolar ridge reconstruction and/or preservation using root form bioglass cones. *J Clin Periodontol* 25(10): 832-9.

# Interaction between ossceram nano and angiopore

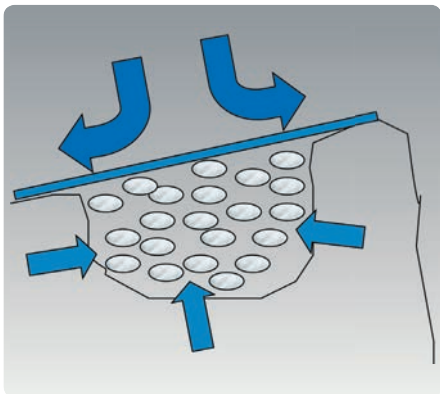
## ossceram nano and angiopore



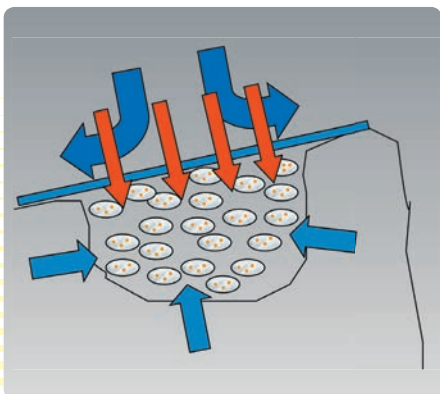
Dentist Andreas Kraus, Olsbrücken (Germany)



Bone development measures are usually implemented under very unfavourable conditions. The bacteria responsible for loss of bone cause a biofilm to form, which conventional methods find very difficult to remove. The augmentation site may become inflamed as a result and thereby undermine the likely success of any treatment.



Conventional membrane and HA alone - the connective tissue is held back, but nothing more, and formation of new bone occurs very slowly.



The angiopore selectively permeable membrane permits the growth of blood vessels from all sides, while the biphasic ossceram nano supports the formation of new bone.

The interaction between the bone-grating material and the membrane is of critical importance to the success of bone development measures. ossceram nano and alveoprotect provide a perfect example of this.

The angiopore selectively permeable membrane offers the augmentation site reliable protection against the growth of connective tissue, while also permitting angiogenesis via 'angiopores', so regeneration of the bone is also supported from the membrane side. ossceram nano, a biphasic and highly porous bone-grafting material with a nanostructured surface, is designed in such a way that the quickly absorbed  $\beta$ -TCP element permits the growth of blood vessels and bone cells, thereby supporting the formation of new bone. At the same time, the very slowly absorbed HA element, which accounts for 60%, ensures the augmented volume is retained.


In addition, the effective control of the bacteria in the biofilm provided by HELBO therapy can ensure the risk of inflammation and problems affecting wound healing are reduced at the augmentation site.

*ossceram nano* is a highly biocompatible, fully synthetic, two-phase calcium phosphate ceramic consisting of

- 60 % hydroxyapatite (HA) and
- 40 %  $\beta$ -tricalcium phosphate ( $\beta$ -TCP).

Consequent bone regeneration is supported by this mineralogical composition, morphology analogous to bone and the resulting resorption characteristics.

While  $\beta$ -TCP arranges itself quickly within the bone structure and is replaced by newly formed bone, the hydroxyapatite element ensures long-term volume stability with low initial shrinkage.



Micro- and macroporosity (magnification 25x)


The high porosity in conjunction with the nano-structured surface stimulates the formation of new bone thanks to

- **Microporosity**  
For optimal diffusion of biological materials and quick ion exchange.
- **Macroporosity**  
For quick blood vessel invasion and osseous organization.


The clearly visible nano structure of the surface supports the formation of bone and hence creates perfect preconditions for the attachment of

- Serum proteins
- Collagen fibers
- Osteoblasts

In in-vitro studies the *ossceram nano* particles were colonized by osteoblasts already after a few days.



nano structure (magnification 1000x)



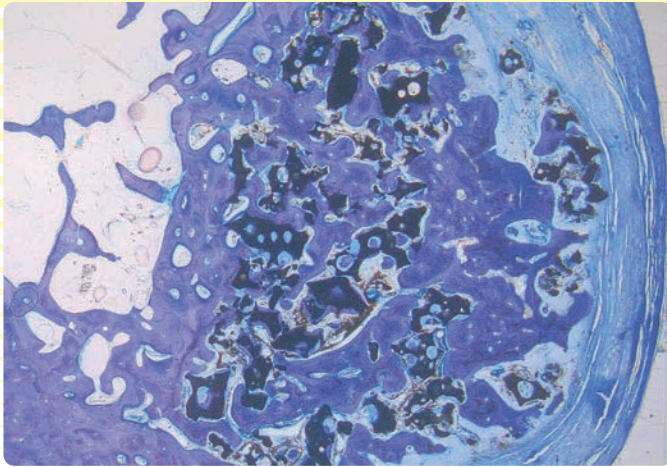
SaOs-2 osteoblasts on *ossceram nano* (magnification 1000x)  
(The cover picture show a SEM photo with *ossceram nano* in false color)

# The safe and user-friendly bone-grafting material

## Properties

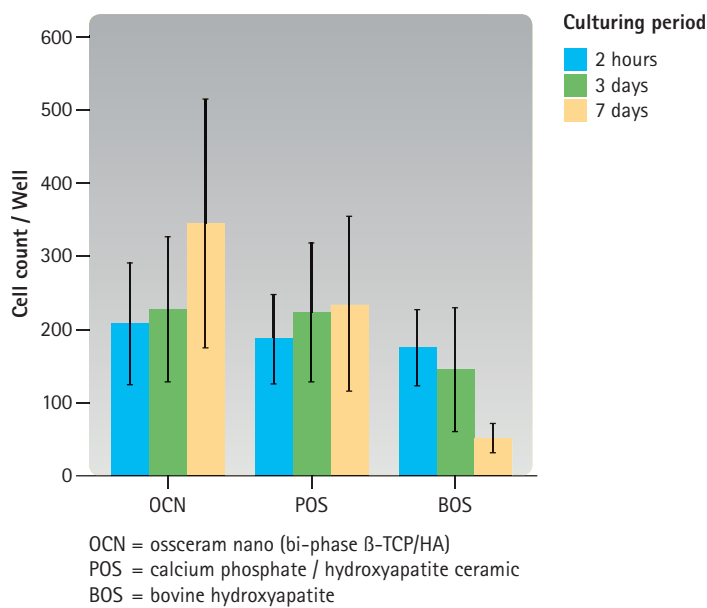
*ossceram nano* granules produce a highly porous, regenerative matrix:

- Volume stability with low initial shrinkage
- Maximum space for the penetration by blood vessels and for regeneration of the vital bone
- Fast and reliable formation of new bone with long-term remodelling into purely vital bone



## Better efficiency

A comparison of *ossceram nano* with a synthetic calcium sulphate / hydroxyapatite ceramic and a natural bovine hydroxyapatite showed significantly better proliferation of osteoblasts on the *ossceram nano* surface.





## Application

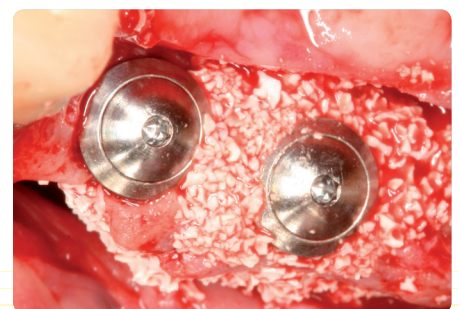
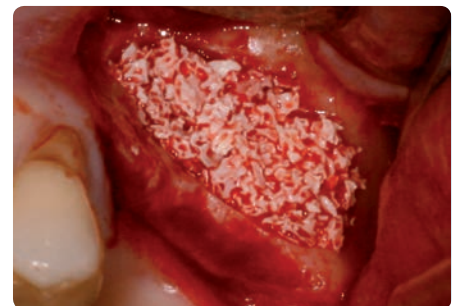
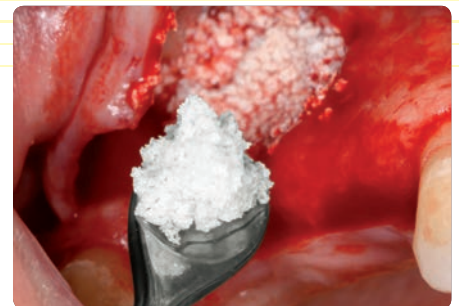After rehydration with

- blood from the defect region
- sterile sodium chloride solution or
- venous blood

*ossceram nano* can be easily and safely applied with the tray.

The rehydrated *ossceram nano* particles adhere firmly to the tray.

Once they are applied, the particles retain their position thanks to the spherical granules and do not need to be condensed.



## Indication

Sinus floor elevation, external

Preferred granule size: 0.8 – 1.5 mm

Sinus floor elevation, internal

Preferred granule size: 0.5 – 1.0 mm

Small and large defects around implants

Preferred granule size: 0.5 – 1.0 mm

Lateral augmentation

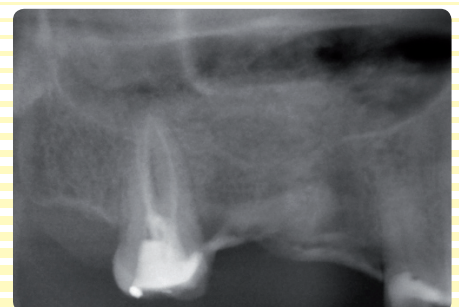
Preferred granule size: 0.5 – 1.0 mm

Cysts and other bone defects in the jaw area

Preferred granule size: depending on the extent of the bone defect

## Radiopacity

The radiopacity allows safe control and reliable documentation of the treatment result.

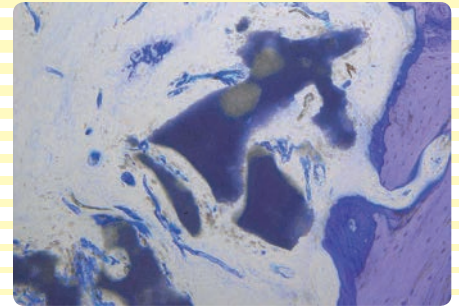
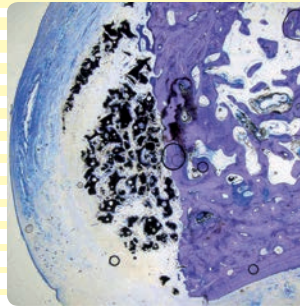


## Remodelling process of *ossceram nano*

### Healing period – 4 weeks

Formation of new bone, mainly starting from the basal direction, can be observed.

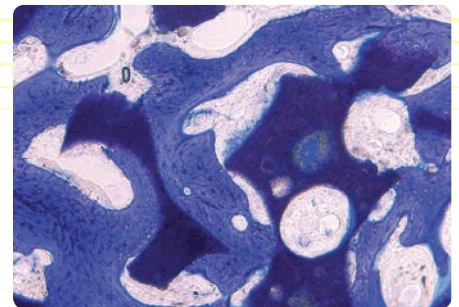
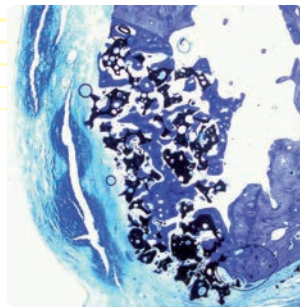
Initial signs of osteoid formation can be detected between the granules.



### Healing period – 8 weeks

The augmentation material is fully integrated into the hard tissue.

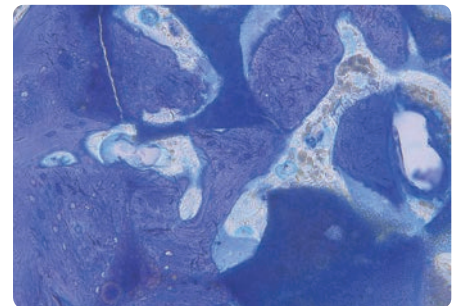
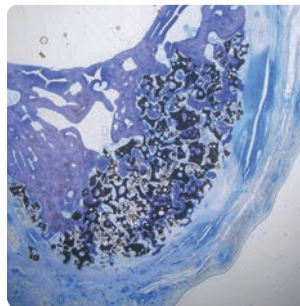
The individual granules appear to be embedded in the mesh-bone.



### Healing period – 12 weeks

Complete osteoconductive integration of the bone substitute material in the mature bone is achieved.

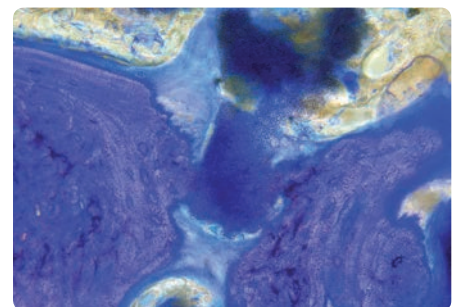
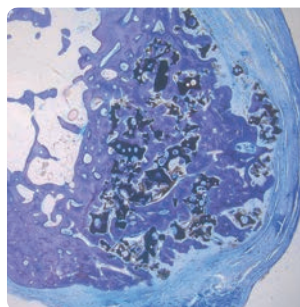
The individual granules are surrounded by newly formed bone tissue and linked with each other via hard tissue bridges.



### Healing period – 24 weeks

Most of the original mesh-bone has been transformed into lamellar bone.

Surface degradation and the detection of resorption lacunae in addition to a slightly mineralized bone matrix are signs of functional remodelling.



Overview image (12.5 x)

Detailed image (400 x)

## Further reading

### Publications

D. Rothamel et al., Oberflächenstruktur, Biokompatibilität und Hartgeweberegeneration, Zeitschrift für Orale Implantologie 2/2009, S. 90-98

This publication is available as a special print.

The selective permeable membrane angiopore is porcine in origin and promotes bone formation in a special manner. On the one hand, the compact fibre structure protects the augmentation from the connective tissue so that the bone has sufficient

time to regenerate itself. On the other hand, the micro-fibrillar "angiopores" serve as a 'guide rail' for the infiltration of blood vessels so that the regeneration of the bone is also supported from the membrane side.

The angiopore membrane in a thickness 0.3 to 0.5 mm with a barrier function of approx. 4 to 5 weeks is particularly suitable

- for younger patients with good wound healing,
- in combination with autogenic or allogenic bone grafting material,
- for small lateral augmentations and bone defects,
- with intact periosteum
- for covering perforated nasal mucus membranes

The angiopore DL membrane in the thickness 0.6 to 0.8 mm with the extended barrier function of approx. 6 to 7 weeks is particularly suitable

- for the treatment of older patients
- when using synthetic or bovine bone grafting material
- for large augmentations
- in case the periosteum is damaged

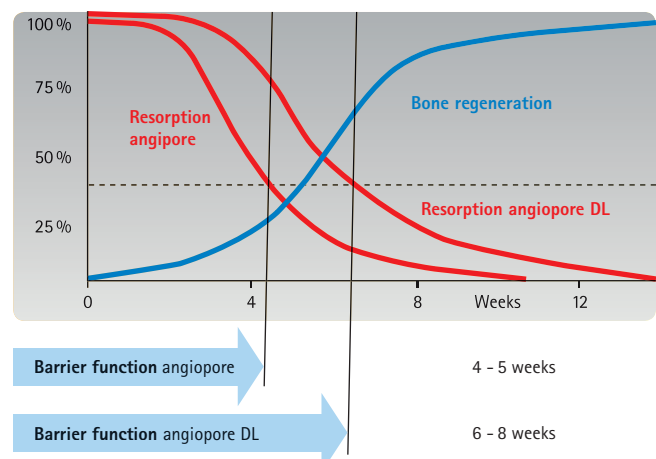
## Application

angiopore can be cut to size both quickly and easily. Once moist, the membrane, which adheres itself to the bone or the surface at the augmentation site, retains its shape and is easy to apply without the need for any additional fixatives.

## Indication

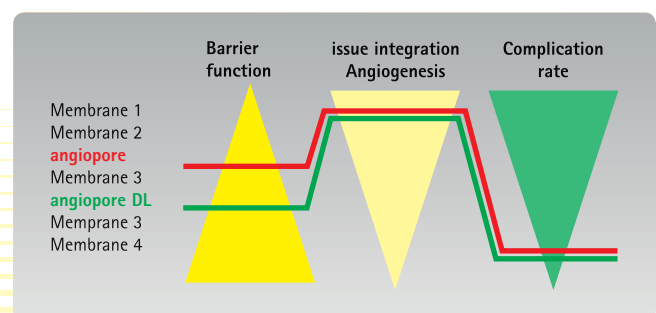
- Surgery-related bone defects and bone wall defects
- Sinus floor augmentation and to support the Schneiderian membrane
- Alveolar ridge augmentation
- Alveolar ridge reconstruction as part of a prosthetic restoration
- Treatment of fenestration defects
- Periodontal bone defects (defects involving one to three walls, class I and II functional defects)
- Peri-implantar dehiscence defects
- Following root resection, cyst removal, removal of retinated teeth, and resection of miscellaneous bone damage
- In or on extraction alveoli following dental extraction
- Immediate or subsequent augmentation involving implants in extraction alveoli

Adequate barrier function for GBR/GTR applications



The duration of the barrier function depends on the thickness of the membrane and the rate of the remodelling process, which is very strongly dependent upon the patient. In the duration of the barrier function mentioned, maintenance of 45% to 50% of the original thickness is taken as a basis.


Properties of different collagen membranes Resorption



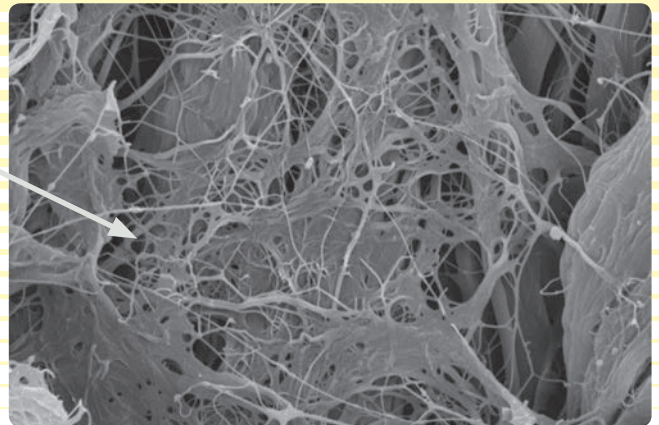
Modified according to Rothamel et. al. (Clinical Oral Implants Research 2008, 16:369-378)

In comparison to other membranes, the barrier function of angiopore lies in the midfield. That of angiopore DL is approx. 1 to 2 weeks longer than with angiopore. In angiogenesis both membranes are in the top group. The same is also true for the complication rate, which is extremely low.


## Safe barrier function and angiogenesis



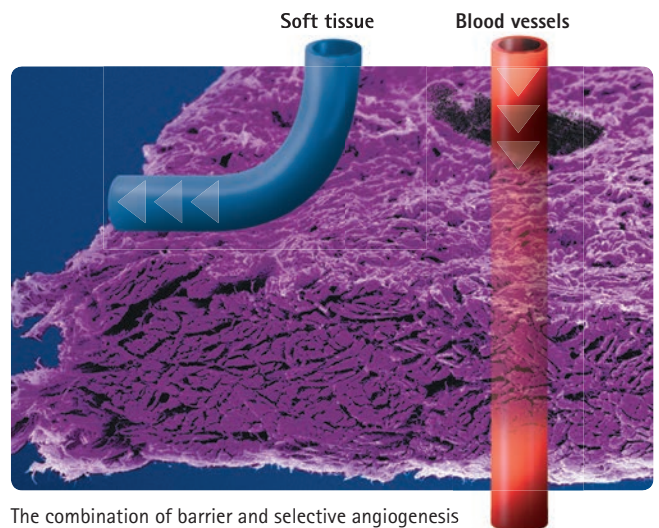
One can clearly recognise the fibrillar collagen structure with the retractions of the angiogenic pores.



The micro-fibrillar collagen within the "angiopores" is quickly absorbed and serves as a 'guide rail' for proliferating.

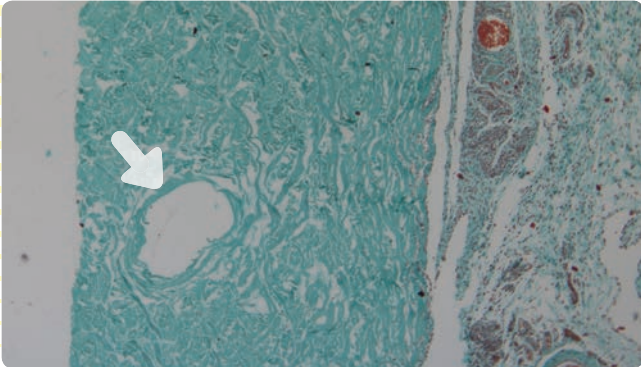


The compact fibre structures guarantee an ideal barrier function, in order to prevent fast growing soft tissue infiltrating the defect.



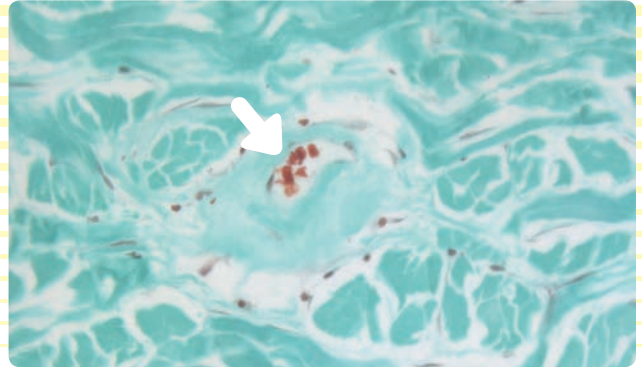
The combination of barrier and selective angiogenesis permits early vascularisation with shielding of the augmentation at the same time.

### Histology: 7 days




After seven days, good tissue integration into adjacent tissues can already be established. The "angiopores" (arrow) which are appropriated for revascularisation are well differentiated.

### Histology: 4 weeks



Naturally occurring "angiopores" in the membrane serve infiltrating blood vessels (arrow) with erythrocytes as a 'guide rail' and ensure fast vascularisation of the underlying augmentation.

### Histology: 3 months



56 days after subcutaneous implantation in the rat, the membrane is seen to be fully integrated into adjacent tissues, the fibrillar collagen structure is completely abolished.

Histological examinations at the University of Cologne showed that the membrane was already integrated into adjacent tissues after only a short period of time.

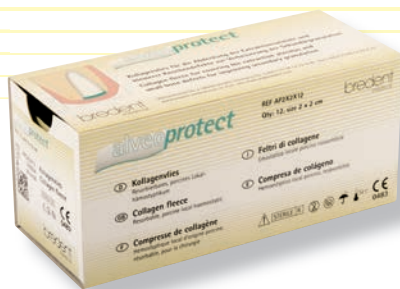After 4 weeks, vascularisation of "angiopore" could be determined in the membrane - the barrier function was still intact.

After 3 months, the membrane was completely integrated into adjacent tissues.

# Order information

## alveoprotect

- Maintains and stabilises the jaw bone and simplifies implantation later on
- The pH neutrality positively influences soft tissue regeneration and reduces inflammatory effects
- Supports the formation of coagulum and is an ideal framework for the adhesion of thrombocytes, fibroblasts and osteoblasts



Technical data:

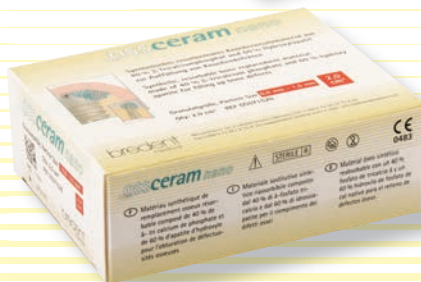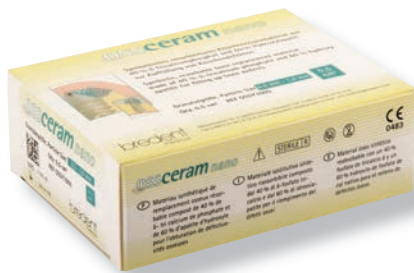pH value	7,0 neutral
Barrier function	yes
Haemostyptic	yes
Soft tissue reaction	positive
Resorption	2-4 weeks

**alveoprotect** collagen fleece  
12 membranes 20 x 20 mm, individually sterile packed

REF AP2x2x12

## ossceram nano

- The  $\beta$ -TCP proportion is replaced by newly developed bon within a short time
- The optimized HA proportion contains the volume of the augmentation
- The nano-structure encourages new bone formation through optimal adhesion of serum proteins and collagen fibres



**ossceram nano** in 2 grain sizes

Grain size	Volume	REF	Colour
0.5 - 1.0 mm	0.5 cc	OSSY1005	Teal
0.5 - 1.0 mm	1.0 cc	OSSY1010	Teal
0.8 - 1.5 mm	1.0 cc	OSSY1510	Red
0.8 - 1.5 mm	2.0 cc	OSSY1520	Red

## angiopore selective permeable membrane

- Compact fibre structures for the safe barrier function towards quickly infiltrating soft tissue
- Pores with micro-fibrillar collagen as a 'guide rail' for angiogenesis
- Two thicknesses with different lengths of barrier function
- Low complication rate



### angiopore selective permeable membrane

Double sterile packed (pouch in pouch)

Gamma sterilized

Thickness	Size	REF
approx. 0,3 - 0,5 mm	15 x 20 mm	AP051520
approx. 0,3 - 0,5 mm	20 x 30 mm	AP052030
approx. 0,3 - 0,5 mm	35 x 45 mm	AP053545
approx. 0,6 - 0,8 mm	15 x 20 mm	APDL1520
approx. 0,6 - 0,8 mm	20 x 30 mm	APDL2030
approx. 0,6 - 0,8 mm	35 x 45 mm	APDL3545

## HELBO-Therapie

Pathogenic bacteria, which find the perfect conditions to thrive in the biofilm, can cause inflammation in the oral cavity leading to a loss of hard and soft tissue. Many scientific studies have shown that HELBO therapy is able to deal with these bacterial infections and prevent inflammation. The process has also proven its worth in prophylactic terms with its successful record of preventing the development of disease.

### HELBO® Professional-Set Plus

REF HE109020

in HELBO® cardboard case

HELBO TheraLite Laser®

(available in red, blue, or silver)

HELBO® battery set incl. charger

HELBO Blue Photosensitizer® 0.1 ml and 0.5 ml

HELBO 3D Pocket Probe® 1 pack of 5

HELBO 2D Spot Probe® 1 pack of 5

Information pack

incl. team training

and a practical guide to HELBO

therapy

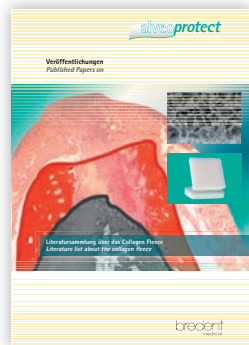

# Regeneration

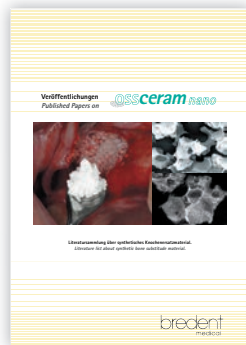
The complete solution for the alveolar ridge




Other offers that may be of interest to you



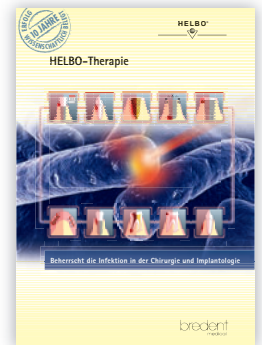
REF 000 366 EX



REF 000 365 EX



REF 000 461 GB



REF 000 429 GB

**bredent**  
medical

bredent medical GmbH & Co.KG  
Weissenhorner Str. 2 | 89250 Senden | Germany  
Tel. (+49) 0 73 09 / 8 72-4 40  
Fax (+49) 0 73 09 / 8 72-4 44  
www.bredent-medical.com  
e-mail info-medical@bredent.com

